

## REVIEW

# Comparison of Tl-201 with Tc-99m-labeled myocardial perfusion agents: Technical, physiologic, and clinical issues

Purushothaman Kailasnath, PhD,<sup>a</sup> and Albert J. Sinusas, MD<sup>a,b</sup>

### OVERVIEW

Currently, there is a considerable body of experimental and clinical literature on the use of thallium 201 and technetium 99m-labeled tracers for detection of coronary artery disease (CAD), detection of myocardial viability, and risk stratification of patients. This article reviews some of the potential advantages and disadvantages of the newer Tc-99m-labeled tracers relative to Tl-201. The basic myocardial kinetic properties and biodistribution of the commonly used Tc-99m-labeled perfusion tracers will be compared with those of Tl-201. The clinical value of the Tc-99m-labeled perfusion tracers will then be compared with that of Tl-201 imaging.

From imaging physics and radiation safety perspectives, the Tc-99m-labeled tracers are superior. The shorter half-life of the Tc-99m-labeled perfusion tracers allows for injection of higher doses of the tracer. The higher 140-keV emissions from Tc-99m result in reduced scatter and attenuation than that associated with the principal 78-keV emission from Tl-201. These physical advantages of the Tc-99m-labeled tracers result in improved image quality, especially in obese patients. Cost and tracer availability also may favor Tc-99m-labeled perfusion tracers over Tl-201. However, biologic properties of these Tc-99m-labeled perfusion tracers may offset these advantages.

The most widely used Tc-99m-labeled perfusion tracers, Tc-99m sestamibi and Tc-99m tetrofosmin, which are currently approved for clinical use, do not track myocardial flow as well as Tl-201 does. Hence the

Tc-99m-labeled perfusion tracers may have biologic disadvantages for myocardial stress perfusion imaging relative to Tl-201. This may reduce the sensitivity of these agents for detection of subcritical CAD. The quest for a Tc-99m-labeled equivalent of Tl-201 (ie, a tracer with superior imaging qualities and flow-tracking capabilities) has led to the development of several new Tc-99m-labeled perfusion tracers. The most notable new agent is bis (N-ethoxy, N-ethyl dithiocarbamate) nitrido Tc-99m (V) (Tc-99m N-NOET), which many investigators consider the technetium equivalent of Tl-201. However, Tc-99m N-NOET is a neutral compound with kinetic properties very different from Tl-201. The behavior of Tc-99m N-NOET is more similar to another neutral compound, Tc-99m teboroxime. Dynamic imaging may be required to take full advantage of the neutral Tc-99m-labeled tracers, which have higher myocardial extraction than Tl-201.

Other issues relevant to myocardial tracer kinetics are the behavior of the tracer in other organs (biodistribution), the manner in which the tracer differentially clears from normal and ischemic regions (redistribution), and the ways in which uptake and clearance of the tracers are influenced by myocardial viability. Myocardial perfusion imaging is often conducted in conjunction with exercise stress or different forms of pharmacologic stress to augment regional flow heterogeneity. Each of these stressors has unique effects on the coronary vasculature, which may also influence the kinetics of each of the radio-labeled perfusion agents differently. These differences must also be considered when selecting a tracer-stressor combination.

The substantial differences in myocardial uptake and clearance kinetics and biodistribution among each of the Tc-99m-labeled perfusion tracers and Tl-201 should be considered in the clinical application of perfusion imaging. Each of the available perfusion tracers has unique advantages and disadvantages, which must be considered for optimal application of these agents.

From the Departments of Diagnostic Radiology<sup>a</sup> and Medicine,<sup>b</sup> Yale University School of Medicine, New Haven, Conn.

Reprint requests: Albert J. Sinusas, MD, Yale University School of Medicine, Nuclear Cardiology, PO Box 208042, TE-2, New Haven, CT 06520-8042; [albert.sinusas@yale.edu](mailto:albert.sinusas@yale.edu).

J Nucl Cardiol 2001;8:482-98.

Copyright © 2001 by the American Society of Nuclear Cardiology.

1071-3581/2001/\$35.00 + 0 43/1/115078

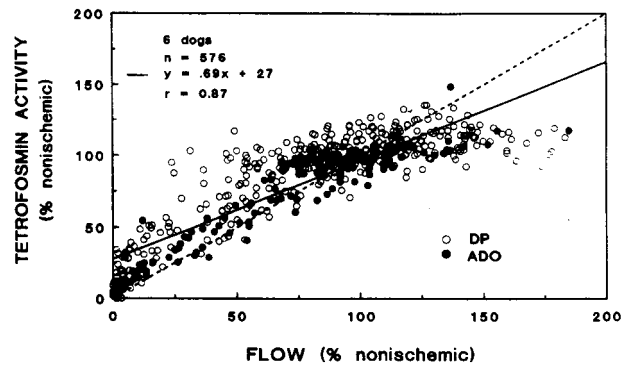
doi:10.1067/mnc.2001.115078

## KINETICS OF RADIOTRACERS: BASIC PRINCIPLES

Important kinetic features of any radiotracer include (1) the first-pass myocardial extraction, which relates to the ability of a radiotracer to track flow in a linear fashion, (2) myocardial washout (clearance), which will be affected by regional flow and radiotracer concentrations, (3) myocardial retention (or accumulation), which is in part a function of cell membrane integrity or viability, and (4) redistribution of the myocardial uptake over time, which is caused by differential regional clearance. In the early phase after tracer injection, blood laden with the tracer permeates the capillaries. The tracer in the capillaries moves across the cell membranes into the cells by means of diffusive or active processes. In this early phase the tracer is extracted from the blood and accumulates in the cell. Subsequently, the tracer starts to leave the cell, or wash out, into the extracellular space or back into the blood. As long as the mechanisms of cellular inflow are stronger than those responsible for outflow, the tracer continues to accumulate in the cells. The rate of accumulation in this secondary phase is less than that in the early phase. *Retention* is used to describe the equilibration of radiotracer activity established in the cells in the postinjection phase. *Clearance* or *washout* describes the phase in which the efflux of tracer from the cell is greater than the influx. The tracer kinetics in the myocardium will also be influenced by the amount of tracer present in the arterial blood supply to the myocardium, which in turn is closely related to the kinetics of the tracer in other organs.

### Myocardial Uptake: Linearity With Flow

How well tracer uptake tracks flow is the feature of tracer kinetics most emphasized in the literature. This feature has been attributed to first-pass extraction. Linear flow tracking occurs when all of the tracer delivered by flow is taken up by the tissue, a process that is not limited by tissue properties. At low flow the myocardium takes up the entire tracer delivered by blood, and therefore the uptake is limited by the delivery of the tracer by flow. At high flow uptake is constrained by the permeability properties of cell membranes or becomes diffusion limited. Tracers that do not track flow well demonstrate roll off of uptake at high flows. The roll-off phenomenon is an indication that the tissue properties are limiting the uptake. The uptake of such tracers will be influenced by the state of the tissue and would be more strongly influenced by changes in tissue permeability. Experiments in which tracer uptake is compared with an independent measurement of flow demonstrate that uptake versus flow behavior is generally nonlinear. At low flow, uptake is linear to



**Figure 1.** Normalized Tc-99m tetrofosmin activity and microsphere flow in an experimental model of coronary occlusion. Hearts were excised at 15 minutes after injection of Tc-99m tetrofosmin to determine if the early poststress distribution of Tc-99m tetrofosmin accurately reflected stress-induced flow heterogeneity. *Filled circles* represent segments from dogs subjected to adenosine (ADO) stress. *Open circles* represent segments from dogs subjected to dipyridamole (DP) stress. Correlations were derived from pooled data (dogs, n = 6; segments, n = 576). At higher flows (>2 mL/min/g) Tc-99m tetrofosmin uptake underestimated flow. (From Sinusas et al. J Nucl Med 1994;35:664-71. Reprinted with permission from the Society of Nuclear Medicine.)

flow, whereas at high flow, uptake tends to become constant regardless of the flow. This behavior for Tc-99m tetrofosmin is shown in Figure 1.

An important corollary to this observed behavior is that the uptake of highly diffusive tracers (ie, tracers that are flow limited) may not be significantly influenced when cell membrane properties change from normal. Hence inferences about membrane state cannot, in general, be made from uptake of these tracers. Only when tissue permeability diminishes significantly from normal will the uptake versus flow of these tracers begin to demonstrate roll-off behavior. However, if the tracer uptake already shows signs of diffusion limitations under normal flow conditions, we may expect that uptake will be influenced by changes in membrane properties. In fact, diffusion-limited tracers may prove to be better indicators of tissue viability.

### Myocardial Uptake and Retention: Effect of Viability on Kinetics

The assessment of myocardial viability requires selection of tracers on the basis of more criteria than a single issue such as linearity in flow tracking. In general, tracer retention is an accurate predictor of viability. Low myocardial activity indicates low flow and hence identifies the tissue as not viable with high confidence. High relative myocardial activity indicates normal or high flow, especially for tracers with minimal roll off, and

identifies the tissue as viable with high confidence. However, considerable uncertainty exists when myocardial activity falls within the intermediate range, representing flow states in which the tissue cannot clearly be categorized as ischemic.

### Myocardial Redistribution

Redistribution imaging is one of the techniques used to enhance the contrast between normal and ischemic tissue. Redistribution results from the differential clearance of a tracer from different myocardial regions. The process of redistribution involves clearance of the tracer that has accumulated in the cell back into the blood and drainage through intracellular spaces. Thus redistribution can take place by means of more than one pathway, and all these pathways require transport across cell membranes. Because the membrane properties are less limiting to transport for linear tracers, the clearance rates are generally high and are sometimes even comparable to extraction rates. For example, the wash-in and washout rates of Tl-201 are comparable in ventricular myocytes of newborn rats.<sup>1</sup> However, for diffusion-limited tracers (ie, tracers that show roll off with increasing flow), the clearance rates are substantially slower than the wash-in rates. In this regard, the slower washout of Tc-99m sestamibi and Tc-99m tetrofosmin could be attributed to the natural affinity of the cell membranes to these lipophilic tracers or cellular retention related to transmembrane potential. Another factor that affects clearance is the amount of tracer in the blood pool, which is related to the kinetics of the tracer in other organs and to excretion of the tracer. Thus tracer redistribution will be affected by many factors, including tracer permeability, volume of distribution, flow rates, blood-pool concentration, and cellular integrity.

A summary of available knowledge on tracers, their structure, the mechanisms of transfer across the cell membranes, and the effect of flow and tissue properties on tracer uptake will provide a better understanding of the way in which the kinetics of a tracer influences clinical application. Such a systematic understanding of tracer functioning during myocardial perfusion imaging will help one to better apply perfusion imaging for detection of CAD and assessment of myocardial viability.

### DIFFERENCES IN STRUCTURE AND CELLULAR EXCHANGE OF AVAILABLE PERFUSION TRACERS

Tl-201 is used in the form of ionic thallos chloride. The uptake of Tl-201 is associated with movement of the

Tl<sup>+</sup> cations, which is dominated by active Na<sup>+</sup>,K<sup>+</sup>-ATPase transport processes.<sup>2</sup> Hence factors influencing these active pathways would affect the uptake of Tl-201. The first-pass myocardial extraction fraction of Tl-201 is 82% to 88%, which is relatively high.<sup>3</sup>

The Tc-99m-labeled complexes are either lipophilic cationic or lipophilic neutral. Because cell membranes are lipid structures, highly lipophilic neutral molecules are naturally attracted to these membranes. Furthermore, because membranes are more negatively charged at the mitochondrial level than at the sarcolemmal level, cationic tracers such as Tc-99m sestamibi enter the cell and then concentrate in the mitochondria.<sup>4</sup>

Tc-99m sestamibi is a lipophilic cationic complex of 6 isonitriles, which is generally taken up by a process of passive diffusion, although secondary active phenomena may play a role. The uptake and accumulation of Tc-99m sestamibi are related to the transmembrane potential. Metabolic changes that alter the uptake of Tc-99m sestamibi have also been demonstrated to alter the transmembrane potential. Leppo and Meerdink<sup>5</sup> examined the myocardial transmicrovascular transport of Tc-99m sestamibi in a blood-perfused, isolated rabbit heart model. The average fractional extraction of Tc-99m sestamibi (39% ± 9%) was significantly less than that of Tl-201 (73% ± 10%). The *in vivo* first-pass myocardial extraction of Tc-99m sestamibi is thought to be intermediate (approximately 55%-68%).<sup>6</sup> Labeling of the compound with Tc-99m is relatively easy and rapid, although the process requires heat.

Tc-99m tetrofosmin is a newer lipophilic cationic complex, which uses a diphosphine ligand and can be rapidly prepared from a kit.<sup>7-9</sup> Metabolic blockers have been shown to cause a strong decrease in cellular accumulation of Tc-99m tetrofosmin, whereas channel inhibitors have little effect. The myocardial first-pass extraction of Tc-99m tetrofosmin is 54%, with slow myocardial clearance and slow redistribution.<sup>10</sup>

The Tc-99m-labeled boronic acid adduct of technetium dioxime (BATO) complex, Tc-99m teboroxime, is a neutral lipophilic radiotracer that demonstrates high myocardial extraction (>90%), rapid myocardial uptake proportional to flow, and rapid myocardial clearance.<sup>11-13</sup>

Tc-99m N-NOET is a highly lipophilic neutral complex that has a high first-pass myocardial extraction of 75% to 85%, which is comparable to that of Tl-201. In general, Tc-99m N-NOET, being lipophilic and neutral, is attracted to the cell membrane. The transport of Tc-99m N-NOET is not influenced by many metabolic and ion transport inhibitors. However, calcium channel blockers can reduce myocardial Tc-99m N-NOET accumulation, whereas calcium channel activators enhance it.<sup>14</sup>

## MYOCARDIAL UPTAKE RELATIVE TO FLOW

Tracers that track flow well demonstrate linear uptake versus flow over a wide range of flow. For such flow-limited tracers the cells take up the entire amount of tracer delivered by flow. Increases in flow lead to increased delivery of the tracer, which in turn causes proportional increases in uptake. Because the diffusion properties of cell membranes do not limit uptake, alterations of the cell membranes would generally not affect tracer uptake versus flow behavior. Flow-limited tracers may not be good indicators of viability. Tc-99m teboroxime would be a good example of a tracer in this category.<sup>13</sup> In an open chest canine model of prolonged occlusion and reperfusion, Chang et al<sup>15</sup> demonstrated that myocardial Tc-99m teboroxime regional activity 2 minutes after injection is an index of flow, independent of myocardial viability. Although the initial distribution of Tc-99m teboroxime may not be a good marker of viability, early Tc-99m teboroxime uptake may be the most appropriate index for the early noninvasive assessment of reperfusion after acute myocardial infarction. However, this approach would necessitate immediate and rapid imaging (1-2 minutes) after injection of the radiotracer. Tc-99m N-NOET is the other neutral lipophilic Tc-99m-labeled radiotracer, which appears to track flow in a fairly linear fashion, even at higher flow induced by pharmacologic stress.<sup>16</sup>

The other available Tc-99m-labeled tracers, such as Tc-99m sestamibi and Tc-99m tetrofosmin, are diffusion limited and do not track flow as well as Tc-99m teboroxime or even Tl-201 does at higher flows induced by exercise or pharmacologic stress.<sup>10,17</sup> However, in the presence of normal flows or conditions of low flow, the uptake of Tc-99m sestamibi,<sup>18,19</sup> Tc-99m tetrofosmin,<sup>20</sup> and Tl-201<sup>18,19</sup> is linearly related to flow.

## EFFECT OF MYOCARDIAL VIABILITY ON TRACER RETENTION

As outlined previously, Tc-99m sestamibi and Tc-99m tetrofosmin are not pure flow tracers and are not retained in necrotic areas.<sup>21-24</sup> Therefore Tc-99m sestamibi and Tc-99m tetrofosmin, like Tl-201, are markers of myocardial viability. If Tc-99m sestamibi is administered during coronary occlusion, the distribution of Tc-99m sestamibi correlates with flow and can quantitatively delineate the regions at risk.<sup>21,22</sup> Thus Tc-99m sestamibi imaging can provide a clinical marker of myocardial regions at risk, thus providing the basis for risk stratification of patients after acute myocardial infarction. However, in the presence of necrosis, the myocardial distribution of Tc-99m sestamibi is critically

dependent on both when the injection is given relative to reperfusion and when the imaging is performed after tracer injection.<sup>22,25</sup>

Although the myocardial uptake and retention of these tracers are altered by myocardial necrosis, the *in vivo* myocardial kinetics of both Tl-201 and Tc-99m sestamibi is not significantly altered by ischemia.<sup>18</sup> In the presence of postischemic dysfunction (myocardial stunning), the myocardial uptake of both Tl-201 and Tc-99m sestamibi is proportional to flow.<sup>18,26</sup> The uptake of Tl-201, which tracks flow well, is generally unaffected by hypoxia, stunning, or low-flow ischemia unless irreversible (severe) injury is present.<sup>3,27-29</sup> A tracer demonstrating diffusion-limited myocardial uptake would theoretically be more sensitive to metabolic dysfunction and membrane disruption.

## CLEARANCE AND REDISTRIBUTION

Tl-201 clearance, like its uptake, is quite rapid. Because a substantial component of Tl-201 transport to the cells is due to active cellular transport processes, its clearance rate would be slower in regions where cellular activity is diminished. Tl-201 demonstrates myocardial redistribution, a phenomenon that improves the identification of myocardial ischemia. Tc-99m sestamibi demonstrates less redistribution than Tl-201, and Tc-99m tetrofosmin demonstrates practically no redistribution.

The myocardial capillary permeability of Tl-201 is greater than that of Tc-99m sestamibi, but the parenchymal cell permeability and volume of distribution of Tc-99m sestamibi are much greater than those of Tl-201, which is reflected in a longer residence time within the myocardium for Tc-99m sestamibi. The net result of these differences in the myocellular transport of the 2 radiopharmaceuticals is that little difference is observed in the initial myocardial accumulation of the 2 agents when imaged *in vivo*, although Tc-99m sestamibi demonstrates significantly slower myocardial clearance than Tl-201. Because factors such as mitochondrial membrane potentials can affect the efflux of Tc-99m sestamibi, the redistribution of Tc-99m sestamibi may be strongly influenced by conditions that disrupt the membrane potential, such as severe ischemia.<sup>30</sup> In a canine model of ischemia, both Tl-201 and Tc-99m sestamibi demonstrated a small degree of redistribution in the presence of critical stenosis.<sup>31</sup> Serial myocardial biopsy specimens also demonstrated redistribution in a canine model of occlusion and reperfusion.<sup>32</sup> The tissue kinetics of Tc-99m sestamibi has important implications with regard to the application and timing of clinical Tc-99m sestamibi imaging.<sup>33,34</sup> In fact, Tc-99m sestamibi redistribution has been shown to be clinically relevant both at rest<sup>35,36</sup> and

## Image available in print only

**Figure 2.** Normalized myocardial Tc-99m N-NOET activity versus microsphere flow in the presence of adenosine (A) or dobutamine (B) stress. All data were derived with a canine model of partial coronary occlusion. A, Tc-99m N-NOET activity (*filled circles*) plotted with curves for TI-201 and Tc-99m sestamibi derived from an early series of experiments that used adenosine stress.<sup>17</sup> B, Tc-99m N-NOET (*filled circles*) and TI-201 activity (*open circles*) plotted with curves for Tc-99m sestamibi derived from an early series of experiments that used dobutamine stress.<sup>42</sup> Uptake of Tc-99m N-NOET and that of TI-201 were closely proportional to flow over a wide range of hyperemic flows, during both adenosine and dobutamine stress (flows of 2.5-3 mL/min/g). In contrast, uptake of Tc-99m sestamibi plateaus slightly earlier during adenosine hyperemia (flows of 2-2.5 mL/min/g). Uptake of Tc-99m sestamibi plateaus even earlier during dobutamine-induced hyperemia (flows of ~1 mL/min/g). (Adapted from Calnon et al. *Circulation* 1999;100:1653-9. Reprinted with permission from Lippincott Williams & Wilkins. Copyright © 1999.)

after exercise.<sup>33</sup> Because the myocardial clearance of Tc-99m sestamibi and Tc-99m tetrofosmin is significantly slower than that of TI-201, separate stress and rest injections of the Tc-99m-labeled agents are generally used.

Of the Tc-99m-labeled compounds, Tc-99m N-NOET demonstrates the greatest degree of myocardial redistribution. Several investigators have demonstrated significant early myocardial redistribution of Tc-99m N-NOET in experimental models of ischemia.<sup>37-40</sup> The prominent redistribution of Tc-99m N-NOET has been attributed to the binding of the compound to red blood cells.<sup>38</sup> The myocardial redistribution of Tc-99m N-NOET is comparable to that of TI-201.<sup>37,39</sup> However, under conditions of extremely low flow, relative myocardial TI-201 uptake in the ischemic region normalized more than Tc-99m N-NOET uptake.<sup>39</sup>

### EFFECT OF PHARMACOLOGIC STRESS

Pharmacologic stressors have differential effects on radiotracer myocardial uptake and clearance kinetics. Under conditions of inotropic stress with dobutamine, myocardial uptake of Tc-99m sestamibi plateaus at a lower flow than previously observed during vasodilator stress with either adenosine or dipyridamole.<sup>41,42</sup> Therefore relative myocardial Tc-99m sestamibi activity underestimated microsphere flow at higher flows induced by dobutamine, leading to underestimation of ischemia. The exact mechanism by which a stressor augments flow becomes relevant to tracer kinetics. For example, different stressors may influence different size ranges in the

vascular tree. The changes in flow patterns induced by a stressor may also involve changes in the effective exchange surface membrane, thereby affecting the extraction of the tracer. Wu et al<sup>41</sup> postulated that increased contractility associated with inotropic stress may result in the development of greater intramyocardial pressures, which may alter hydrostatic pressure and in turn fluid and mass transport in the myocardium. Calnon et al<sup>42</sup> suggested that the effect of dobutamine on myocardial uptake may be related to alterations of calcium transport. The myocardial uptake of Tc-99m sestamibi may be diminished by dobutamine-induced calcium influx, which reduced the negative mitochondrial membrane driving potential. The myocardial uptake of Tc-99m N-NOET and that of TI-201 are closely proportional to blood flow during both adenosine and dobutamine stress, suggesting that the adverse effect of dobutamine on Tc-99m sestamibi uptake is a tracer-specific phenomenon rather than a generalized effect.<sup>16</sup> The effects of pharmacologic stress on myocardial uptake of radiotracers are summarized in Figure 2. The clinical implication of this finding is that Tc-99m N-NOET or TI-201 might be preferable to Tc-99m sestamibi when used with dobutamine stress for detection of coronary stenoses.

### BIODISTRIBUTION

The uptake and clearance kinetics of the tracer from all organs and the excretion of the tracer by the liver or kidneys are also relevant to myocardial stress perfusion

**Table 1.** Relative tracer distribution in the heart, liver, and lungs

Authors	Tracer	Time	Heart-liver		Heart-lung	
			Rest	Exercise	Rest	Exercise
Wackers et al <sup>43</sup>	Tl-201	2 h/20 min*	1.4 ± 0.3	2.1 ± 0.3	1.9 ± 0.1	2.3 ± 0.2
Wackers et al <sup>43</sup>	Tc-99m sestamibi	5 min	0.5 ± 0.1	1.3 ± 0.1	1.9 ± 0.2	2.1 ± 0.1
Jain et al <sup>44</sup>	Tc-99m tetrofosmin	5 min	0.8 ± 0.2	1.3 ± 0.4	1.8 ± 0.2	1.9 ± 0.3
Vanzetto et al <sup>14</sup>	Tc-99m N-NOET	5 min	1.4 ± 0.2	1.5 ± 0.2	0.8 ± 0.1	1.4 ± 0.4

\*Rest images were acquired 2 hours after injection; stress images were acquired 20 minutes after injection.

imaging. The uptake and clearance from these organs establish the level of tracer activity in the circulating blood, which in turn affects the myocardial tracer kinetics. Tracer activity in organs adjacent to the heart, such as the lungs and the liver, complicates imaging of the heart. Hence the relative tracer uptake in these organs (ie, biodistribution) and the variation of biodistribution with time are important in the determination of the optimal timing of imaging. The biodistribution of a radiotracer can also be affected by the level of exercise or by the type of pharmacologic stress.

Table 1 summarizes the reported biodistribution of Tl-201,<sup>43</sup> Tc-99m sestamibi,<sup>43</sup> Tc-99m tetrofosmin,<sup>44</sup> and Tc-99m N-NOET.<sup>14</sup> The ratios of activity in the heart are compared with those in neighboring organs (liver and lung) at rest and after exercise. The biodistribution of both Tc-99m sestamibi and Tc-99m tetrofosmin shows considerable change with exercise, which suggests that the kinetics of these tracers was influenced by the degree of stress. In contrast, the heart-liver ratio of Tc-99m N-NOET, which has a superior extraction fraction compared with the other 2 tracers, is comparable at rest and after exercise. Investigators have suggested that Tc-99m tetrofosmin has a relatively faster hepatic clearance than Tc-99m sestamibi, yet both tracers have the same heart-liver contrast ratio with imaging after exercise. The improved heart-liver ratio of Tc-99m tetrofosmin at rest is derived with a same-day stress/rest protocol and therefore may simply reflect increased myocardial uptake from the preceding stress injection.<sup>44</sup>

## CLINICAL APPLICATIONS

### Detection of CAD

**Tl-201 versus Tc-99m sestamibi.** Early single-center studies directly comparing Tl-201 and Tc-99m sestamibi demonstrated comparable sensitivities of both

tracers for detection of CAD<sup>45-47</sup>; one of the largest multicenter studies directly comparing Tl-201 and Tc-99m sestamibi confirmed these results.<sup>48</sup> Many of the patients enrolled in this multicenter study had undergone both planar (n = 284) and single photon emission computed tomography (SPECT) (n = 294 patients) imaging. The sensitivities for detection of significant coronary artery stenosis in 1 of the 3 vascular territories were 85% and 87% for planar Tc-99m sestamibi and Tl-201, respectively. The sensitivities were similar for SPECT imaging (Tc-99m sestamibi, 92%; Tl-201, 90%). However, this early phase III multicenter study suggested that Tc-99m sestamibi imaging may provide improved specificity for detection of CAD. The specificities for detection of significant coronary artery stenosis in 1 of the 3 vascular territories were 95% and 55% for planar Tc-99m sestamibi and Tl-201, respectively. The specificities of SPECT imaging for detection of CAD were less favorable for both radiotracers (Tc-99m sestamibi, 50%; Tl-201, 39%). Although SPECT Tc-99m sestamibi imaging provided slightly improved sensitivity for detection of coronary disease, this was at the expense of specificity. The low specificities reported in this multicenter trial have been attributed to patient referral bias, in that patients with abnormal perfusion study results were preferentially referred for coronary angiography.<sup>49</sup> However, such a justification would not explain the lower specificity of SPECT relative to planar imaging. The low specificity must therefore be partially related to misinterpretation of attenuation artifacts on SPECT imaging.

A meta-analysis was recently performed comparing exercise echocardiography and exercise SPECT imaging for detection of CAD documented by cardiac catheterization.<sup>50</sup> This analysis included 27 studies that evaluated the sensitivity and specificity of SPECT Tl-201 or Tc-99m sestamibi imaging for detection of CAD. Nine of the studies used Tl-201 SPECT, 15 used Tc-99m sestamibi SPECT, and 3 used dual isotope Tl-201

**Table 2.** Summary of studies that compared the accuracy of Tc-99m tetrofosmin with Tl-201 for detection of CAD

Author	Year	No. of patients	Patients with myocardial infarction (%)	Imaging	Stress
Nakajima et al <sup>59</sup>	1993	26	31	SPECT	Exercise
Sridhara et al <sup>60</sup>	1993	50	64	Planar	Exercise
Heo et al <sup>61</sup>	1994	26	15	SPECT	Exercise
Tamaki et al <sup>62</sup>	1994	25	48	SPECT	Exercise
Rigo et al <sup>63</sup>	1994	40	65	Planar	Exercise
Zaret et al <sup>64</sup>	1995	224	50	Planar	Exercise
Cuocolo et al <sup>142</sup>	1996	41	56	SPECT	Adenosine/exercise
Matsunari et al <sup>66</sup>	1996	20	50	SPECT	Exercise
Benoit et al <sup>67</sup>	1996	72	58	Planar/SPECT	Exercise
Shanoudy et al <sup>69</sup>	1998	26	23	SPECT	Dipyridamole

\*Values shown are for adenosine/exercise.  
 †Values shown are for planar imaging/SPECT imaging.  
 ‡Values shown are for detection of ≥50% stenosis/>70% stenosis.

and Tc-99m sestamibi SPECT imaging. The overall sensitivity of exercise SPECT imaging was 87%, although the specificity was only 64%. In this meta-analysis the choice of tracer or the use of visual versus quantitative analysis did not significantly affect accuracy. Recently, limitations have been identified regarding the inclusion criteria used for selection of the studies included in this meta-analysis.<sup>51</sup>

More recent studies suggest that the specificity of SPECT imaging for detection of CAD may be improved with gated SPECT analysis,<sup>52,53</sup> simultaneous analysis of perfusion and function,<sup>53</sup> or application of attenuation correction.<sup>54,55</sup> Analysis of gated SPECT has been useful in separating true fixed perfusion defects from those caused by soft tissue attenuation. This additional information results in an improved specificity of SPECT imaging for detection of CAD.

Ficaro et al<sup>54</sup> were the first to report improved specificity for detection of CAD with the use of nonuniform attenuation correction, using a noncommercial system for simultaneous emission transmission imaging. A recent prospective multicenter trial was performed that compared uncorrected Tc-99m sestamibi SPECT perfusion images and attenuation- and scatter-corrected images for detection of CAD.<sup>55</sup> This multicenter trial demonstrated that the use of attenuation and scatter correction in conjunction with SPECT imaging significantly improved the normalcy rate without reducing the overall sensitivity. However, implementation of attenuation and scatter correction resulted in a reduction in the detection of multivessel disease in the study population.<sup>55</sup>

Although Tc-99m has a higher energy emission (140 keV) than Tl-201 (78 keV), tissue attenuation with Tc-

99m is decreased by only approximately 15%.<sup>56,57</sup> However, the shorter half-life of the Tc-99m-labeled tracers permits injection of much larger doses of radioactivity, yielding improved image quality and allowing for electrocardiography (ECG)-gated image acquisitions. This allows for simultaneous assessment of regional myocardial perfusion and function, which permits better identification of attenuation artifacts.<sup>53</sup>

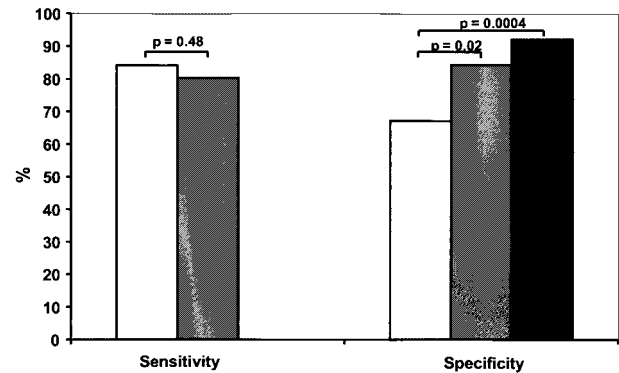
Taillefer et al<sup>58</sup> recently compared the accuracy of Tl-201 and Tc-99m sestamibi SPECT imaging for detection of CAD in women. This prospective study demonstrated comparable sensitivities of these 2 tracers for detection of CAD. However, Tc-99m sestamibi SPECT imaging provided improved specificity, particularly if perfusion and function were evaluated with ECG-gated SPECT. The principal findings of this study are summarized in Figure 3. Differences in specificity were observed depending on the stressor. The improved specificity of Tc-99m sestamibi was seen only in patients undergoing exercise.

**Tl-201 versus Tc-99m tetrofosmin.** Many studies have compared the accuracy of Tc-99m tetrofosmin with that of Tl-201 for detection of CAD.<sup>59-69</sup> All studies have demonstrated reasonable concordance for detection of coronary disease, although some of the studies have demonstrated a slight underestimation of ischemia with Tc-99m tetrofosmin.<sup>59,66,69</sup> The sensitivity and specificity of Tc-99m tetrofosmin for detection of CAD have been variable. This variability is related in part to the presence of myocardial infarction in the population under investigation. These studies are summarized in Table 2. The largest study to evaluate the accuracy of Tl-201 and Tc-99m tetrofosmin for detection of CAD was a phase III

Concordance with Tl-201 (%)	Sensitivity for CAD (%)	Specificity for CAD (%)
83	60	72
68	-	-
83	87	100
89	75	80
81	75	-
60	77	58
82	86/84*	85/92*
100	-	-
-	68/87†	78/89†
76	37/72‡	-

multicenter clinical trial.<sup>64</sup> In this trial 224 patients underwent symptom-limited exercise and rest planar Tl-201 and Tc-99m tetrofosmin imaging. Tc-99m tetrofosmin imaging was performed with a same-day, split-dose planar imaging protocol. Fifty percent of the patients had prior myocardial infarction. Myocardial regions were categorized as normal, ischemic, or infarcted. There was a 60% precise concordance of Tc-99m tetrofosmin and Tl-201 findings. A subset of patients underwent cardiac catheterization (n = 181). The sensitivity and specificity of Tc-99m tetrofosmin for detection of angiographically determined stenosis of 70% or greater in all of the patients were fair (sensitivity, 77%; specificity, 58%), although they declined when the patients without myocardial infarction were excluded (sensitivity, 70%; specificity, 52%). Azzarelli et al<sup>70</sup> recently performed a retrospective analysis of the accuracy of Tc-99m tetrofosmin SPECT imaging for detection of CAD. In this large population (n = 235) with a high incidence of myocardial infarction (66%), the overall sensitivity (95%) and specificity (77%) for detection of any CAD were good. However, the sensitivity (69%) for detection of individual diseased vessels was less favorable, whereas specificity (94%) remained high. As previously demonstrated with Tc-99m sestamibi SPECT imaging, the addition of functional analysis of left ventricular function in conjunction with Tc-99m tetrofosmin imaging improved diagnostic accuracy for the detection of CAD.<sup>71</sup>

**Tl-201 versus Tc-99m N-NOET.** Initial clinical studies suggest that Tc-99m N-NOET myocardial perfusion images are of excellent quality and provide comparable sensitivity to Tl-201 for detection of CAD.<sup>14,72</sup>



**Figure 3.** Sensitivity and specificity of SPECT Tl-201 (open bars) and Tc-99m sestamibi (MIBI; gray bars) perfusion for detection of coronary stenosis of 70% or greater in 85 women with suspected CAD and in 30 women with likelihood of CAD of 5% or lower. Sensitivity for detection of CAD was similar for both tracers. However, Tc-99m sestamibi provided improved specificity. Specificity was improved further by additional analysis of regional wall motion from ECG-gated SPECT Tc-99m sestamibi images (filled bars). (Adapted from Taillefer et al. J Am Coll Cardiol 1999;29:69-77. Reprinted with permission from the American College of Cardiology.)

### Pharmacologic Stress

Although many investigators have reported similar sensitivities between Tc-99m sestamibi and Tl-201 in detection of CAD, these studies generally used exercise<sup>45,47,73</sup> or pharmacologic vasodilation.<sup>74,75</sup>

Simultaneous dipyridamole administration and maximal subjective exercise in patients who are unable to achieve a good exercise level can improve the diagnostic accuracy of Tc-99m sestamibi SPECT.<sup>76</sup> No clinically relevant differences in diagnostic accuracy were demonstrated between Tc-99m sestamibi and Tl-201 SPECT with combined dipyridamole-exercise stress for the evaluation of CAD.<sup>74</sup> As outlined previously, experimental studies suggest that dobutamine Tc-99m sestamibi may have lower sensitivities for detection of CAD than vasodilators because of the earlier roll off.

Several clinical studies have evaluated the efficacy of dobutamine stress Tc-99m sestamibi scintigraphy for detection of CAD. These studies have generally reported acceptable sensitivity (range, 73%-89%) and specificity (range, 69%-100%).<sup>77-82</sup> However, the sensitivity of dobutamine Tc-99m sestamibi scintigraphy for detection of CAD is partly dependent on the severity of the underlying stenosis. Voth et al<sup>79</sup> showed a detection rate of 85% (28/33 patients) for severe stenosis (>70% diameter reduction) but only 50% (12/24 patients) for moderate stenosis (50%-70% diameter reduction) in one or more vessels. Clinical studies have also demonstrated decreased

sensitivity of dobutamine Tc-99m sestamibi scintigraphy for detection of single-vessel disease versus multivessel disease. Senior et al<sup>81</sup> reported a sensitivity of 77% for prediction of multivessel disease but a generally lower sensitivity for detection of single-vessel disease. In their study of 97 patients, Marwick et al<sup>80</sup> showed sensitivities of 89% for detection of multivessel disease but only 71% for detection of single-vessel disease. Thus the sensitivity of dobutamine Tc-99m sestamibi scintigraphy reported in the clinical literature may be falsely elevated because of patient selection. There was a high clinical suspicion for the presence of CAD, multivessel disease, or critical coronary stenosis in many of the patients enrolled in these studies. However, the implications of this bias toward a high sensitivity remain purely speculative and warrant further clinical experimental and clinical evaluation.

There are limited clinical data that have directly compared exercise and pharmacologic stress with Tc-99m tetrofosmin SPECT myocardial perfusion imaging. Levine et al<sup>83</sup> recently examined 31 patients with CAD and 7 patients with a less than 5% likelihood of CAD. All patients underwent separate-day Tc-99m tetrofosmin SPECT imaging at rest and after exercise, dipyridamole, adenosine, and dobutamine stress. Defect extent, severity, and reversibility were less with dipyridamole or dobutamine Tc-99m tetrofosmin SPECT imaging than with exercise Tc-99m tetrofosmin SPECT.

Earlier studies by this group evaluated the effects of different pharmacologic stressors on Tc-99m sestamibi SPECT defect size.<sup>78,84</sup> Santos-Ocampo et al<sup>84</sup> performed Tc-99m sestamibi SPECT imaging after rest, exercise, dipyridamole, and adenosine stress on separate occasions in 20 subjects (10 healthy subjects and 10 patients with known CAD). They observed no significant differences in the myocardial perfusion defects obtained after the 3 different modes of stress, including percentages of defect size, stress deficit, and ischemia; count deficit index; and defect nadir. Thus Tc-99m sestamibi, in combination with either adenosine or dipyridamole infusion, provides imaging data equivalent to the data obtained with exercise.

### **Risk Stratification and Prognosis**

In patients with known CAD, the measurement of resting regional myocardial perfusion and global left ventricular function helps to predict the subsequent occurrence of cardiac events, including myocardial infarction, angina, and sudden death.

The prognostic value of stress Tl-201 scintigraphic assessment of the severity of ischemia and infarction in patients with stable CAD and after myocardial infarction

is well established.<sup>85</sup> The potential of this risk stratification method was first established in 1980 in patients after myocardial infarction<sup>86</sup> and in 1983 in patients with chest pain<sup>87</sup> and in additional patients after uncomplicated myocardial infarction.<sup>88</sup> The best predictor of future cardiac events was the number of ischemic segments in the Tl-201 images.<sup>87</sup> Many subsequent studies have confirmed the prognostic value of exercise-induced ischemia on Tl-201 scintigraphy.<sup>89,90</sup> The number of cardiac events increased exponentially as a function of the number of reversible Tl-201 defects.<sup>89</sup> A normal Tl-201 study result confers an excellent prognosis, independent of the presence or absence of other demonstrable evidence of CAD.<sup>91,92</sup> Tl-201 imaging in conjunction with dipyridamole-induced coronary vasodilation also has great prognostic value.<sup>93,94</sup>

Increased lung uptake of Tl-201 is also an important predictor of cardiac events.<sup>95,96</sup> Increased lung uptake is the result of exercise-induced left ventricular dysfunction, which results in increased Tl-201 uptake in the interstitial space of the lungs caused by elevated left ventricular filling pressure. The presence of increased lung uptake is associated with multivessel CAD and extensive ischemia.<sup>97</sup> With planar imaging, a visual increase of lung uptake is the best predictor of future cardiac events.<sup>96</sup> Quantitative criteria have been established for the assessment of increased lung uptake.<sup>95</sup>

Exercise-induced left ventricular dilatation is another indicator of extensive CAD in Tl-201 scintigraphic studies; it indicates a poor prognosis.<sup>98</sup> Transient left ventricular dilatation is a specific marker of multivessel CAD.<sup>98</sup>

The prognostic value of the Tc-99m-labeled perfusion agents is comparable to that reported for Tl-201 imaging.<sup>99</sup> A normal Tc-99m sestamibi perfusion study result is associated with a very low hard event rate of only 0.6% annually. Berman et al<sup>100</sup> demonstrated the incremental prognostic value of Tc-99m sestamibi perfusion imaging over clinical and exercise electrocardiographic variables in a large population followed up for nearly 2 years. Exercise Tc-99m sestamibi perfusion imaging may provide even greater incremental prognostic value in women than in men.<sup>101,102</sup> As with Tl-201 scintigraphic studies, the extent of hypoperfusion on stress Tc-99m sestamibi perfusion studies provides important prognostic information. In a large retrospective study Hachamovitch et al<sup>103</sup> demonstrated that patients with mild Tc-99m sestamibi perfusion defects had good outcomes, independent of therapy used. In contrast, those with moderate or severe defects had much better outcomes with revascularization than with medical therapy.

Many laboratories are currently performing rest Tl-201/exercise Tc-99m sestamibi dual-isotope myocardial

perfusion SPECT imaging. This dual-isotope protocol appears to offer prognostic value similar to that of single-isotope studies. Berman et al<sup>104</sup> studied 1043 consecutive patients with known or suspected CAD, using a rest Tl-201 and exercise Tc-99m sestamibi dual-isotope SPECT perfusion protocol, with patients followed up for at least 1 year. This study directly compared quantitative analysis with expert visual semiquantitative scoring. There were no significant differences in the areas under receiver operating characteristic curves between quantitative and visual analysis. Thus automatic quantitative analysis of exercise stress myocardial perfusion SPECT was similar to semiquantitative expert visual analysis for prognostic stratification. These findings may be of particular clinical importance in laboratories with less experienced visual interpreters.

In patients with chronic stable angina the resting left ventricular ejection fraction<sup>105</sup> and the exercise ejection fraction<sup>106,107</sup> help predict cardiovascular death or myocardial infarction. In risk stratification the radio-tracer data are independent of the prognostic information obtained at cardiac catheterization. Rest/exercise radionuclide angiography was used to predict subsequent cardiovascular events in 571 stable medically treated patients with symptomatic CAD who underwent catheterization.<sup>108</sup> With a median follow-up of more than 5 years, the peak exercise left ventricular ejection fraction was the best predictor of death. The change in heart rate and the resting end-diastolic volume index were also of prognostic importance. Imaging with the Tc-99m-labeled perfusion agents permits additional evaluation of rest and stress ejection fraction and left ventricular volume, potentially augmenting the prognostic power of perfusion imaging with the Tc-99m-labeled perfusion agents over that of Tl-201 imaging.

### Preoperative Risk Assessment

Dipyridamole stress Tl-201 imaging is helpful in the determination of whether a patient will tolerate peripheral vascular surgery.<sup>109</sup> Pharmacologic stress is usually used because the patients often cannot exercise. In these patients there is a high incidence of CAD.<sup>109</sup> The benefit of preoperative screening with Tl-201 scintigraphy has been confirmed by many investigators.<sup>85</sup> Tl-201 redistribution is the best predictor of cardiac events in patients who are undergoing vascular surgery. Dipyridamole Tl-201 scintigraphy is most helpful in patients who are considered at intermediate risk based on clinical assessment.<sup>110</sup> Using dipyridamole Tl-201 scintigraphy for preoperative screening in patients scheduled for elective vascular surgery, only one study found no association between Tl-201 redistribution evidence of ischemia and

adverse cardiac outcome.<sup>111</sup> The patients were at relatively low risk, and the number of cardiac events (ie, death, recurrent infarction) was quite small. In light of the other data supporting the role of dipyridamole stress Tl-201 scintigraphy for preoperative risk stratification, Tl-201 scintigraphy should be used to screen patients who are undergoing vascular surgical procedures.

Because Tc-99m perfusion agents are comparable to Tl-201 for detection of CAD and myocardial infarction, these tracers should provide similar prognostic information in patients who are undergoing preoperative screening for vascular surgery.<sup>109,110</sup> The assessment of lung uptake remains a major prognostic advantage of Tl-201 imaging over the Tc-99m-labeled agents in the determination of cardiac risk,<sup>96</sup> although analysis of left ventricular dilatation and ejection fraction with Tc-99m-labeled perfusion agents may offset this advantage.

### Treatment and Prognosis in Acute Myocardial Infarction

Tl-201 perfusion imaging and radionuclide assessment of left ventricular function have played important roles in the care of patients with acute myocardial infarction.<sup>88,112,113</sup> At present, information about myocardial perfusion and function can be derived simultaneously with Tc-99m-labeled perfusion agents. In addition, Tc-99m-labeled perfusion agents may provide an index of the amount of myocardium at risk. When treatment modalities directed at reducing infarct size are evaluated, the true area at risk must be determined. Experimental studies have demonstrated that the risk area can be accurately assessed with tomographic Tc-99m sestamibi imaging.<sup>22,114</sup> Assessment of the myocardial area at risk with quantitative planar and SPECT Tc-99m sestamibi imaging is feasible in patients.<sup>115-117</sup> Because Tc-99m tetrofosmin demonstrates no redistribution, this perfusion agent may be even more useful than Tc-99m sestamibi for the determination of myocardium at risk after myocardial infarction.

Measurement of left ventricular function provides important prognostic information after myocardial infarction because the extent of myocardial injury is reflected in global left ventricular function.<sup>112,118</sup> The assessment of left ventricular function after myocardial infarction has proved useful in patients both before and after the advent of thrombolytic therapy.<sup>119</sup> Quantitative information about regional and global left ventricular function can now be obtained in conjunction with Tc-99m-labeled perfusion imaging by performance of either first-pass blood pool studies or ECG-gated SPECT myocardial analysis.

The presence and extent of reversible Tl-201 defects, increased lung uptake, and exercise-induced left ventric-

## Image available in print only

**Figure 4.** Early after myocardial infarction (MI) patients were randomized to dipyridamole (DP) plus submaximal exercise (EX) Tc-99m sestamibi or submaximal exercise Tc-99m sestamibi SPECT imaging. Annual cardiac death or recurrent myocardial infarction rate as a function of summed stress score (SSS), summed difference score (SDS), and summed rest score (SRS) is shown for dipyridamole and exercise Tc-99m sestamibi SPECT imaging. Event rate after myocardial infarction increased as Tc-99m sestamibi defect scores increased. The ability to predict cardiac events was better for dipyridamole Tc-99m sestamibi SPECT than for exercise studies. All event rates were derived from risk-adjusted Cox survival curves. The predictive value of pre-discharge Tc-99m sestamibi SPECT was similar to that previously reported for SPECT Tl-201. *Open bars*, Low; *gray bars*, intermediate; *filled bars*, high. (Adapted from Brown et al. *Circulation* 1999;100:2060-6. Reprinted with permission from Lippincott Williams & Wilkins. Copyright © 1999.)

ular dilatation are predictors of cardiac events. Submaximal exercise Tl-201 scintigraphy is of prognostic value after myocardial infarction.<sup>88</sup> In patients with uncomplicated myocardial infarction, scintigraphic evidence of ischemia better predicted cardiac events than electrocardiographic ST-segment depression, angina, or extent of angiographic disease.<sup>88</sup> The prognostic value of Tl-201 scintigraphy after myocardial infarction has been confirmed by studies using both exercise<sup>120,121</sup> and pharmacologic stress.<sup>93,113</sup> A stepwise logistic regression analysis indicated that resting Tl-201 defect score was a better predictor of death than ejection fraction, although ejection fraction did provide additional prognostic information.<sup>122</sup>

Tl-201 imaging has limitations in the evaluation of patients after thrombolysis. Tl-201 imaging cannot distinguish between infarcted myocardium and hibernating myocardium, both of which may be present early after acute coronary reperfusion.<sup>123</sup> After thrombolysis normal Tl-201 myocardial perfusion images indicate successful reperfusion and myocardial viability. On the other hand, a Tl-201 perfusion defect may represent (1) myocardial infarction with an occluded artery, (2) myocardial infarction with reperfusion occurring too late for myocardial

salvage, or (3) persistent low myocardial blood flow through a critically stenosed artery with persistent viability (hibernating myocardium). The use of 24-hour delayed imaging<sup>124</sup> or resting reinjection of Tl-201<sup>125</sup> has been proposed to detect hibernating myocardium and better define myocardial viability.

After thrombolytic therapy, pre-discharge Tl-201 studies at a low level of exercise provide less reliable prognostic information than that obtained in patients who have not had thrombolytic therapy.<sup>126</sup> This may be the result of plaque instability within the reperfused coronary artery without residual critical stenosis. In a study of 101 patients treated with early thrombolysis who had at least 70% residual stenosis, Tl-201 scintigraphy failed to detect ischemia in 49% of the patients.<sup>127</sup> In this population the absence of ischemia on a pre-discharge Tl-201 stress test was associated with more extensive necrosis and higher peak creatine kinase levels, suggesting minimal salvage despite early reperfusion.

Exercise or pharmacologic Tc-99m sestamibi perfusion imaging has become a widely used alternative to Tl-201 imaging for risk stratification in patients after myocardial infarction. Travin et al<sup>128</sup> demonstrated that the extent of ischemia in exercise Tc-99m sestamibi perfusion imaging after infarction was an important predictor of cardiac events. More recently, pharmacologic vasodilatation has been used early after infarction for risk stratification of patients with myocardial infarction. A large multicenter study used dipyridamole Tc-99m sestamibi 2 to 4 days after myocardial infarction for early risk stratification of patients with acute myocardial infarction.<sup>129</sup> The extent and severity of defect reversibility had significant incremental prognostic value over clinical and stress variables for prediction of in-hospital events and events after discharge (Figure 4).

The prognostic value of ejection fraction after infarction is well established in patients with and without coronary reperfusion or revascularization. Imaging with Tc-99m-labeled agents offers a unique opportunity to assess both perfusion and function simultaneously. The incremental prognostic value of the additional functional assessment in these patients still needs to be proved.

### Assessment of Myocardial Viability

Regional Tl-201 activity after resting injection, imaged early and after redistribution, reflects viable myocardium and can predict improved regional and global ventricular function after revascularization.<sup>124,130-132</sup> Several clinical studies have compared Tc-99m sestamibi with Tl-201 for assessment of myocardial viability. Some of these studies suggest that both agents are fairly comparable for identification of myocardial viability,<sup>35,36,133</sup>

whereas others have suggested that Tc-99m sestamibi may underestimate myocardial viability.<sup>134,135</sup> Identification of reversible and viable myocardium can be greatly enhanced with Tc-99m sestamibi if an additional redistribution image is acquired after the rest Tc-99m sestamibi injection or if the severity of reduction in Tc-99m sestamibi activity within irreversible defects is considered.<sup>35</sup> Resting Tc-99m sestamibi redistribution frequently occurs in patients with chronic CAD.<sup>35,36</sup> Acquisition of Tc-99m sestamibi redistribution images enhances detection of viable myocardium and predicts functional recovery after revascularization.<sup>35,36</sup>

Dilsizian et al<sup>35</sup> studied 54 patients with chronic CAD with a mean ejection fraction of  $34\% \pm 14\%$ , using stress/redistribution/reinjection Tl-201 tomography. These patients underwent same-day rest/stress Tc-99m sestamibi imaging with the same exercise protocol within 5 days of the Tl-201 imaging. The concordance regarding reversibility of myocardial defects between Tl-201 stress/redistribution/reinjection and same day rest/stress Tc-99m sestamibi studies was 75%. When an additional 4-hour redistribution image was acquired in 18 patients after the injection of Tc-99m sestamibi at rest, 6 of 16 discordant irreversible regions (38%) on the rest/stress Tc-99m sestamibi study became reversible, thereby increasing the concordance between Tl-201 and Tc-99m sestamibi studies to 82%.

Maurea et al<sup>36</sup> examined 31 patients with proven CAD and left ventricular dysfunction (ejection fraction  $39\% \pm 9\%$ ), using resting Tc-99m sestamibi tomography with initial imaging (1 hour after injection) and delayed imaging (5 hours after injection). Within 1 week of Tc-99m sestamibi imaging, all patients underwent rest-distribution Tl-201 imaging. Twenty-four percent of segments with a severe reduction of tracer uptake demonstrated increased relative tracer activity on delayed images (from  $43\% \pm 8\%$  to  $60\% \pm 8\%$ ,  $P < .001$ ) and were considered to demonstrate Tc-99m sestamibi redistribution. In the 8 patients studied before and after revascularization, 83% of segments with Tc-99m sestamibi redistribution and abnormal left ventricular function showed functional recovery after revascularization, whereas 96% of segments without Tc-99m sestamibi redistribution did not show functional recovery.

In an earlier study by Maurea et al,<sup>136</sup> planar rest and 4-hour delayed redistribution Tl-201 uptake and resting planar Tc-99m sestamibi uptake (1 hour after injection) were compared in 29 men with angiographically proven CAD and regional ventricular dysfunction (left ventricular ejection fraction,  $35\% \pm 9\%$ ). In this study regions were separated on the basis of severity of regional dysfunction as determined by equilibrium radionuclide ventriculography. Myocardial Tc-99m ses-

## Image available in print only

**Figure 5.** Scatterplot showing correlation of quantitative regional activities of Tl-201 (after redistribution) and Tc-99m sestamibi among segments with significant regional dysfunction in patients undergoing revascularization. *Open symbols* represent those segments with improved regional function (reversible dysfunction) after revascularization; *filled symbols* represent segments with irreversible ventricular dysfunction. Quantitative Tl-201 imaging and Tc-99m sestamibi SPECT imaging were comparable for prediction of functional recovery in patients who underwent coronary revascularization. (Adapted from Udelson et al. *Circulation* 1994; 89:2552-61. Reprinted with permission from Lippincott Williams & Wilkins. Copyright © 1994.)

tambi activity was comparable to early and delayed Tl-201 activity in segments with normal or mildly depressed function; however, myocardial Tc-99m sestamibi activity was lower than Tl-201 activity in regions with akinesis or dyskinesis.

Altehoefer et al<sup>135</sup> compared Tc-99m sestamibi uptake at rest with the presence or absence of fluorine 18 deoxyglucose (FDG) uptake as assessed with positron emission tomography (PET) in 111 consecutive patients. Only 5% to 11% of segments with severely reduced Tc-99m sestamibi uptake at rest ( $\leq 30\%$  of peak activity) were viable, and 80% to 84% were nonviable based on PET FDG uptake. Myocardial segments with a moderate to severe reduction in Tc-99m sestamibi uptake at rest (31%-70% of peak) were generally viable, although the segmental correlation of relative uptake of Tc-99m sestamibi and FDG was only fair ( $n = 1443$ ,  $r = 0.61$ ,  $P < .001$ ). Thus, in patients with CAD, Tc-99m sestamibi uptake suggests myocardial viability, although the uptake may underestimate myocardial viability in comparison with FDG PET in segments with moderately reduced Tc-99m sestamibi activity.

Udelson et al<sup>133</sup> compared both qualitative and quantitative analyses of rest and redistribution Tl-201 activity and Tc-99m sestamibi activity 1 hour after rest injection in 31 patients with CAD and left ventricular

dysfunction. There was high concordance (87%) between regional Tl-201 activity on delayed redistribution images and regional sestamibi activity by both semiquantitative visual analysis and quantitative analysis. A subset of patients (n = 18) had follow-up echocardiography after revascularization. Tl-201 and Tc-99m sestamibi demonstrated similar positive predictive values (Tl-201, 75%; Tc-99m sestamibi, 80%) and negative predictive values (Tl-201, 92%; Tc-99m sestamibi, 96%) for recovery of regional ventricular dysfunction after revascularization (Figure 5). Thus quantitative analysis of Tc-99m sestamibi SPECT images can differentiate viable from nonviable myocardium and can predict reversibility of significant regional wall motion abnormalities after revascularization with results comparable to those obtained with Tl-201.

Kauffman et al<sup>137</sup> prospectively compared resting myocardial uptake of Tl-201 (early and 3-hour delayed images) with rest Tc-99m sestamibi uptake (1 hour after injection) in the same patients, using quantitative SPECT imaging. Tc-99m sestamibi uptake was not significantly different than uptake for delayed Tl-201 images, but was significantly greater than initial Tl-201 uptake in patients with both mild and severe Tl-201 redistribution.<sup>137</sup> The concordance rate between Tc-99m sestamibi uptake and delayed Tl-201 uptake was 88% ( $\kappa = 0.66$ ),<sup>137</sup> thereby confirming the early finding of Udelson et al.<sup>133</sup> Tc-99m sestamibi ECG-gated SPECT myocardial perfusion imaging at rest allows assessment of both perfusion and wall motion, which significantly improves the sensitivity and overall accuracy for determination of viability in comparison with perfusion alone.<sup>138</sup>

Tc-99m tetrofosmin imaging may also be useful for assessment of myocardial viability,<sup>139-141</sup> providing results comparable to rest Tl-201 imaging. The sensitivity of rest Tc-99m tetrofosmin imaging for assessment of myocardial viability may be improved with quantitative analysis of defect severity<sup>139,141</sup> or administration of nitroglycerin.<sup>140</sup>

Early clinical studies demonstrate the presence of marked myocardial redistribution of Tc-99m N-NOET similar to that of Tl-201.<sup>72</sup> Therefore Tc-99m N-NOET may also be useful for identification of viable dysfunctional regions with resting ischemia.

## CONCLUSION

The Tc-99m-labeled perfusion agents appear comparable to Tl-201 for detection of CAD and may offer an advantage in obese patients with excessive attenuation as a result of the improved image quality of these agents. An important advantage that the Tc-99m-labeled perfusion agents offer is the ability to obtain quantitative informa-

tion about regional and global myocardial function in conjunction with information about perfusion. There may be a slight disadvantage of Tc-99m sestamibi or Tc-99m tetrofosmin for detection of subcritical disease, particularly with pharmacologic stress. The Tc-99m-labeled perfusion agents also seem to provide comparable prognostic information and may offer some clear advantages over Tl-201 in the setting of acute myocardial infarction. In the future the neutral Tc-99m-labeled agents may permit a more quantitative assessment of regional myocardial flow, although application of these agents will probably require dynamic imaging. Each of the Tc-99m-labeled perfusion agents has unique properties, which need to be considered for the optimization of imaging protocols and clinical application.

## References

1. Maublant J, Moins N, Gachon P. Uptake and release of two new Tc-99m labeled myocardial blood flow imaging agents in cultured cardiac cells. *Eur J Nucl Med* 1989;15:180-2.
2. Hunter DR, Haworth RA, Goknur AB, Hegge JO, Berkoff HA. Control of thallium and sodium fluxes in isolated adult rat heart cells by anthopleurin-A, verapamil and magnesium. *J Mol Cell Cardiol* 1986;18:1125-32.
3. Weich H, Strauss H, Pitt B. The extraction of thallium-201 by the myocardium. *Circulation* 1977;56:188-91.
4. Backus M, Piwnica-Worms D, Hockett D, Kronauge J, Lieberman M, Ingram P, et al. Microprobe analysis of Tc-MIBI in heart cells: calculation of mitochondrial membrane potential. *Am J Physiol* 1993;265:C178-87.
5. Leppo JA, Meerdink DJ. Comparison of the myocardial uptake of a technetium-99m-labeled isonitrile analogue and thallium. *Circ Res* 1989;65:632-9.
6. Marshall R, Leidholt E, Zhang DY, et al. Technetium-99m-hexakis 2-methoxy-2-isobutyl isonitrile and thallium-201 extraction, washout, and retention at varying coronary flow rates in rabbit heart. *Circulation* 1990;82:998-1007.
7. Kelly JD, Forster AM, Higley B, Archer CM, Booker FS, Canning LR, et al. Technetium-99m-tetrofosmin as a new radiopharmaceutical for myocardial perfusion imaging. *J Nucl Med* 1993;34:222-7.
8. Higley B, Smith FW, Smith T, Gemmell HG, Das Gupta P, Gvozdanovic DV, et al. Technetium-99m-1,2-bis[bis(2-ethoxyethyl)phosphino]ethane: human biodistribution, dosimetry and safety of a new myocardial perfusion imaging agent. *J Nucl Med* 1993;34:30-8.
9. Sinusas AJ, Shi Q, Saltzberg MT, Vitols P, Jain D, Wackers FJ, et al. Technetium-99m-tetrofosmin to assess myocardial blood flow: experimental validation in an intact canine model of ischemia. *J Nucl Med* 1994;35:664-71.
10. Glover DK, Ruiz M, Yang JY, Smith WH, Watson DD, Beller GA. Myocardial <sup>99m</sup>Tc-tetrofosmin uptake during adenosine-induced vasodilatation with either a critical or mild coronary stenosis: comparison with <sup>201</sup>Tl and regional myocardial blood flow. *Circulation* 1997;96:2332-8.
11. Leppo JA, Meerdink DJ. Comparative myocardial extraction of two technetium-labeled BATO derivatives (SQ30217, SQ32014) and thallium. *J Nucl Med* 1990;31:67-74.
12. Rumsey W, Rosenspire K, Nunn A. Myocardial extraction of teboroxime: effect of teboroxime interaction with blood. *J Nucl Med* 1992;33:94-101.

13. Beanlands R, Muzik O, Nguyen N, Petry N, Schwaiger M. The relationship between myocardial retention of technetium-99m tetrofosmin and myocardial blood flow. *J Am Coll Cardiol* 1992;20:712-9.
14. Vanzetto G, Fagret D, Pasqualini R, Mathieu J, Chossat F, Machecourt J. Biodistribution, dosimetry, and safety of myocardial perfusion imaging agent <sup>99m</sup>Tc-NOET in healthy volunteers. *J Nucl Med* 2000;41:141-8.
15. Chang P, Shi Q-X, Saltzberg M, Maniowski P, Vitols P, Stubbs J, et al. Myocardial distribution and clearance of Tc-99m-tetrofosmin during reperfusion after acute myocardial infarction. *Circulation* 1992;86:1-707.
16. Calnon DA, Ruiz M, Vanzetto G, Watson DD, Beller GA, Glover DK. Myocardial uptake of (99m)Tc-N-NOET and (201)Tl during dobutamine infusion. Comparison with adenosine stress. *Circulation* 1999;100:1653-9.
17. Glover DK, Ruiz M, Edwards NC, Cunningham M, Simanis JP, Smith WH, et al. Comparison between <sup>201</sup>Tl and <sup>99m</sup>Tc sestamibi uptake during adenosine-induced vasodilation as a function of coronary stenosis severity. *Circulation* 1995;91:813-20.
18. Sinusas A, Watson D, Cannon J, Beller G. Effect of ischemia and postischemic dysfunction on myocardial uptake of technetium-99m-labeled methoxyisobutyl isonitrile and thallium-201. *J Am Coll Cardiol* 1989;14:1785-93.
19. Canby R, Silber S, Pohost G. Relations of the myocardial imaging agents <sup>99m</sup>Tc-MIBI and <sup>201</sup>Tl to myocardial blood flow in a canine model of myocardial ischemic insult. *Circulation* 1990;81:289-96.
20. Sinusas AJ, Shi Q, Saltzberg MT, Vitols P, Jain D, Wackers FJ, et al. Technetium-99m-tetrofosmin to assess myocardial blood flow: experimental validation in an intact canine model of ischemia. *J Nucl Med* 1994;35:664-71.
21. Verani M, Jeroudi M, Mahmarian J, Boyce T, Borges-Neto S, Patel B, et al. Quantification of myocardial infarction during coronary occlusion and myocardial salvage after reperfusion using cardiac imaging with technetium-99m hexakis 2-methoxyisobutyl isonitrile. *J Am Coll Cardiol* 1988;12:1573-81.
22. Sinusas A, Trautman K, Bergin J, Watson D, Ruiz M, Smith W, et al. Quantification of area at risk during coronary occlusion and degree of myocardial salvage after reperfusion with technetium-99m methoxyisobutyl isonitrile. *Circulation* 1990;82:1424-37.
23. Freeman I, Grunwald A, Hoory S, Bodenheimer M. Effect of coronary occlusion and myocardial viability on myocardial activity of technetium-99m-sestamibi. *J Nucl Med* 1991;32:292-9.
24. Glover DK, Ruiz M, Koplán BA, Watson DD, Beller GA. <sup>99m</sup>Tc-tetrofosmin assessment of myocardial perfusion and viability in canine models of coronary occlusion and reperfusion. *J Nucl Med* 1999;40:142-9.
25. Beller GA, Glover DK, Edwards NC, Ruiz M, Simanis JP, Watson DD. <sup>99m</sup>Tc-sestamibi uptake and retention during myocardial ischemia and reperfusion. *Circulation* 1993;87:2033-42.
26. Moore CA, Cannon J, Watson DD, Kaul S, Beller GA. Thallium 201 kinetics in stunned myocardium characterized by severe postischemic systolic dysfunction. *Circulation* 1990;81:1622-32.
27. Friedman B, Beihn R, Friedman J. The effect of hypoxia on thallium kinetics in cultured chick myocardial cells. *J Nucl Med* 1987;28:1453-60.
28. Leppo JA, Macneil PB, Moring AF, Apstein CS. Separate effects of ischemia, hypoxia, and contractility on thallium-201 kinetics in rabbit myocardium. *J Nucl Med* 1986;27:66-74.
29. Leppo J. Myocardial uptake of thallium and rubidium during alterations in perfusion and oxygenation in isolated rabbit hearts. *J Nucl Med* 1987;28:878-85.
30. Maublant J. Kinetics on a cellular level. In: Zaret B, Beller G, editors. *Nuclear cardiology: state of the art and future directions*. St. Louis: Mosby; 1999. p. 13-26.
31. Sinusas AJ, Bergin JD, Edwards NC, Watson DD, Ruiz M, Makuch RW, et al. Redistribution of <sup>99m</sup>Tc-sestamibi and <sup>201</sup>Tl in the presence of a severe coronary artery stenosis. *Circulation* 1994;89:2332-41.
32. Li Q, Solot A, Frank T, Wagner H, Becker L. Myocardial redistribution of technetium-99m methoxy isobutyl isonitrile (SESTAMIBI). *J Nucl Med* 1990;31:1069-76.
33. Taillefer R, Primeau M, Costi P, Lambert R, Leveille J, Latour Y. Technetium-99m-sestamibi myocardial perfusion imaging in detection of coronary artery disease: comparison between initial (1-hour) and delayed (3-hour) postexercise images. *J Nucl Med* 1991;32:1961-5.
34. Sinusas A, Zaret B. Heart: coronary artery disease. In: Wagner H, Szaboz Z, editors. *Principles of nuclear medicine*. Philadelphia: Saunders; 1995. p. 789-819.
35. Dilsizian V, Arrighi JA, Diodati JG, Quyyumi AA, Alavi K, Bacharach SL, et al. Myocardial viability in patients with chronic coronary artery disease. Comparison of <sup>99m</sup>Tc-sestamibi with thallium reinjection and [<sup>18</sup>F]fluorodeoxyglucose [published erratum appears in *Circulation* 1995;91:3026]. *Circulation* 1994;89:578-87.
36. Maurea S, Cuocolo A, Soricelli A, Castelli L, Squame F, Imbriaco M, et al. Myocardial viability index in chronic coronary artery disease: technetium-99m-methoxy isobutyl isonitrile redistribution. *J Nucl Med* 1995;36:1953-60.
37. Ghezzi C, Fagret D, Arvieux CC, Mathieu JP, Bontron R, Pasqualini R, et al. Myocardial kinetics of Tc-N-NOET: a neutral lipophilic complex tracer of regional myocardial blood flow. *J Nucl Med* 1995;36:1069-77.
38. Johnson G III, Nguyen KN, Pasqualini R, Okada RD. Interaction of technetium-99m-N-NOET with blood elements: potential mechanism of myocardial redistribution. *J Nucl Med* 1997;38:138-43.
39. Vanzetto G, Calnon DA, Ruiz M, Watson DD, Pasqualini R, Beller GA, et al. Myocardial uptake and redistribution of <sup>99m</sup>Tc-N-NOET in dogs with either sustained coronary low flow or transient coronary occlusion: comparison with <sup>201</sup>Tl and myocardial blood flow. *Circulation* 1997;96:2325-31.
40. Petruzella F, Ruiz M, Katsiyiannis P, Watson DD, Pasqualini R, Beller GA, et al. Optimal timing for initial and redistribution technetium 99m-N-NOET image acquisition. *J Nucl Cardiol* 2000;7:123-31.
41. Wu JC, Yun JJ, Heller EN, Dione DP, DeMan P, Liu YH, et al. Limitations of dobutamine for enhancing flow heterogeneity in the presence of single coronary stenosis: implications for technetium-99m-sestamibi imaging. *J Nucl Med* 1998;39:417-25.
42. Calnon DA, Glover DK, Beller GA, Vanzetto G, Smith WH, Watson DD, et al. Effects of dobutamine stress on myocardial blood flow, <sup>99m</sup>Tc sestamibi uptake, and systolic wall thickening in the presence of coronary artery stenoses: implications for dobutamine stress testing. *Circulation* 1997;96:2353-60.
43. Wackers FJ, Berman DS, Maddahi J, Watson DD, Beller GA, Strauss HW, et al. Technetium-99m hexakis 2-methoxyisobutyl isonitrile: human biodistribution, dosimetry, safety, and preliminary comparison to thallium-201 for myocardial perfusion imaging. *J Nucl Med* 1989;30:301-11.
44. Jain D, Wackers FJ, Mattered J, McMahon M, Sinusas AJ, Zaret BL. Biokinetics of technetium-99m-tetrofosmin: myocardial perfusion imaging agent: implications for a one-day imaging protocol. *J Nucl Med* 1993;34:1254-9.
45. Kiat H, Maddahi J, Roy LT, Van Train K, Friedman J, Resser K, et al. Comparison of technetium 99m methoxy isobutyl isonitrile and thallium 201 for evaluation of coronary artery disease by planar and tomographic methods. *Am Heart J* 1989;117:1-11.
46. Taillefer R, Lambert R, Dupras G, Gregoire J, Leveille J, Essiambre R, et al. Clinical comparison between thallium-201 and Tc-99m-methoxy isobutyl isonitrile (hexamibi) myocardial perfusion imaging for detection of coronary artery disease. *Eur J Nucl Med* 1989;15:280-6.
47. Kahn J, McGhie I, Akers M, et al. Quantitative rotational tomography with TI-201 and Tc99m 2-methoxy-isobutyl-isonitrile: a direct comparison in normal individuals and patients with coronary artery disease. *Circulation* 1989;79:1282-93.

48. Maddahi J, Kiat H, Friedman J, Berman D, Van Train K, Garcia E. Technetium-99m-sestamibi myocardial perfusion imaging for evaluation of coronary artery disease. In: Zaret B, Beller G, editors. Nuclear cardiology: state of the art and future directions. St. Louis: Mosby; 1993. p. 191-200.
49. Rozanski A, Diamond GA, Forrester JS, Berman DS, Morris D, Swan HJ. Alternative referent standards for cardiac normality: implications for diagnostic testing. *Ann Intern Med* 1984;101:164-71.
50. Fleischmann KE, Hunink MG, Kuntz KM, Douglas PS. Exercise echocardiography or exercise SPECT imaging? A meta-analysis of diagnostic test performance. *JAMA* 1998;280:913-20.
51. Kymes S, Bruns D, Shaw L, Gillespie K, Fletcher J. Anatomy of a meta-analysis: a critical review of "Exercise echocardiography or exercise SPECT imaging? A meta-analysis of diagnostic test performance." *J Nucl Cardiol* 2000;7:599-615.
52. Mannting F, Morgan-Mannting M. Gated SPECT with technetium-99m-sestamibi for assessment of myocardial perfusion abnormalities. *J Nucl Med* 1993;34:601-8.
53. Depuey E, Rozanski A. Using gated technetium-99m-sestamibi SPECT to characterize fixed myocardial defects as infarct or artifact. *J Nucl Med* 1995;36:952-5.
54. Ficaro EP, Fessler JA, Shreve PD, Kritzman JN, Rose PA, Corbett JR. Simultaneous transmission/emission myocardial perfusion tomography. Diagnostic accuracy of attenuation-corrected <sup>99m</sup>Tc-sestamibi single-photon emission computed tomography. *Circulation* 1996;93:463-73.
55. Hendel RC, Berman DS, Cullom SJ, Follansbee W, Heller GV, Kiat H, et al. Multicenter clinical trial to evaluate the efficacy of correction for photon attenuation and scatter in SPECT myocardial perfusion imaging. *Circulation* 1999;99:2742-9.
56. Watson D, Smith W. Sestamibi and the tissue crosstalk. *J Nucl Med* 1990;31:1409-11.
57. Garcia E, Cooke D, Van Train K, et al. Technical aspects of myocardial SPECT imaging with technetium-99m sestamibi. *Am J Cardiol* 1990;66:23E-31E.
58. Taillefer R, DePuey EG, Udelson JE, Beller GA, Latour Y, Reeves F. Comparative diagnostic accuracy of Tl-201 and Tc-99m sestamibi SPECT imaging (perfusion and ECG-gated SPECT) in detecting coronary artery disease in women. *J Am Coll Cardiol* 1997;29:69-77.
59. Nakajima K, Taki J, Shuke N, Bunko H, Takata S, Hisada K. Myocardial perfusion imaging and dynamic analysis with technetium-99m tetrofosmin. *J Nucl Med* 1993;34:1478-84.
60. Sridhara B, Braat S, Rigo P, Itti R, Cload P, Lahiri A. Comparison of myocardial perfusion imaging with technetium-99m tetrofosmin versus thallium 201 in coronary artery disease. *Am J Cardiol* 1993;72:1015-9.
61. Heo J, Cave V, Wasserleben V, Iskandrian A. Planar and tomographic imaging with technetium 99m-labeled tetrofosmin: correlation with thallium-201 and coronary angiography. *J Nucl Cardiol* 1994;1:317-24.
62. Tamaki N, Takahashi N, Kawamoto M, Torizuka T, Tadamura E, Yonekura Y, et al. Myocardial tomography using technetium-99m-tetrofosmin to evaluate coronary artery disease. *J Nucl Med* 1994;35:594-600.
63. Rigo P, Leclercq B, Itti R, Lahiri A, Braat S. Technetium-99m-tetrofosmin myocardial imaging: a comparison with thallium-201 and angiography. *J Nucl Med* 1994;35:587-93.
64. Zaret BL, Rigo P, Wackers FJ, Hendel RC, Braat SH, Iskandrian AS, et al. Myocardial perfusion imaging with <sup>99m</sup>Tc tetrofosmin. Comparison to <sup>201</sup>Tl imaging and coronary angiography in a phase III multicenter trial. Tetrofosmin International Trial Study Group. *Circulation* 1995;91:313-9.
65. Cuocolo A, Soricelli A, Nicolai E, Squame F, Nappi A, Sullo P, et al. Technetium-99m-tetrofosmin regional myocardial uptake at rest: relation to severity of coronary artery stenosis in previous myocardial infarction. *J Nucl Med* 1995;36:907-13.
66. Matsunari I, Fujino S, Taki J, Senma J, Aoyama T, Wakasugi T, et al. Comparison of defect size between thallium-201 and technetium-99m tetrofosmin myocardial single-photon emission computed tomography in patients with single-vessel coronary artery disease. *Am J Cardiol* 1996;77:350-4.
67. Benoit T, Vivegnis D, Lahiri A, Itti R, Braat S, Rigo P. Tomographic myocardial imaging with technetium-99m tetrofosmin. Comparison with tetrofosmin and thallium planar imaging and with angiography. *Eur Heart J* 1996;17:635-42.
68. Khattar RS, Hendel RC, Crawley JC, Wackers FJ, Rigo P, Zaret BL, et al. Improved diagnostic accuracy of planar imaging with technetium 99m-labeled tetrofosmin compared with thallium-201 for the detection of coronary artery disease. *J Nucl Cardiol* 1997;4:291-7.
69. Shanoudy H, Raggi P, Beller GA, Soliman A, Ammermann EG, Kastner RJ, et al. Comparison of technetium-99m tetrofosmin and thallium-201 single-photon emission computed tomographic imaging for detection of myocardial perfusion defects in patients with coronary artery disease. *J Am Coll Cardiol* 1998;31:331-7.
70. Azzarelli S, Galassi AR, Foti R, Mammata C, Musumeci S, Giuffrida G, Tamburino C. Accuracy of <sup>99m</sup>Tc-tetrofosmin myocardial tomography in the evaluation of coronary artery disease. *J Nucl Cardiol* 1999;6:183-9.
71. Takahashi N, Tamaki N, Tadamura E, Kawamoto M, Torizuka T, Yonekura Y, et al. Combined assessment of regional perfusion and wall motion in patients with coronary artery disease with technetium-99m tetrofosmin. *J Nucl Cardiol* 1994;1:29-38.
72. Fagret D, Marie PY, Brunotte F, Giganti M, Le Guludec D, Bertrand A, et al. Myocardial perfusion imaging with technetium-99m-Tc NOET: comparison with thallium-201 and coronary angiography. *J Nucl Med* 1995;36:936-43.
73. Larock MP, Cantineau R, Legrand V, Kulbertus H, Rigo P. <sup>99m</sup>Tc-MIBI (RP-30) to define the extent of myocardial ischemia and evaluate ventricular function. *Eur J Nucl Med* 1990;16:223-30.
74. Cramer MJ, Verzijlbergen JF, Van der Wall EE, Niemeyer MG, Zwinderman AH, Ascoop CA, et al. Head-to-head comparison between technetium-99m-sestamibi and thallium-201 tomographic imaging for the detection of coronary artery disease using combined dipyridamole-exercise stress. *Coron Artery Dis* 1994;5:787-91.
75. Amanullah AM, Kiat H, Friedman JD, Berman DS. Adenosine technetium-99m sestamibi myocardial perfusion SPECT in women: diagnostic efficacy in detection of coronary artery disease. *J Am Coll Cardiol* 1996;27:803-9.
76. Candell-Riera J, Santana-Boado C, Castell-Conesa J, Aguade-Bruix S, Olona M, Palet J, et al. Simultaneous dipyridamole/maximal subjective exercise with <sup>99m</sup>Tc-MIBI SPECT: improved diagnostic yield in coronary artery disease. *J Am Coll Cardiol* 1997;29:531-6.
77. Pennell D, Underwood S, Swanton R, Walker J, Ell P. Dobutamine thallium myocardial perfusion tomography. *J Am Coll Cardiol* 1991;15:1471-9.
78. Herman S, LaBresh K, Santos-Ocampo C, et al. Comparison of dobutamine and exercise using technetium-99m sestamibi imaging for the evaluation of coronary artery disease. *Am J Cardiol* 1994;73:164-9.
79. Voth E, Baer F, Theissen P, Schneider C, Sechtem U, Schicha U. Dobutamine <sup>99m</sup>Tc-MIBI single-photon emission tomography: non-exercise-dependent detection of haemodynamically significant coronary artery stenoses. *Eur J Nucl Med* 1994;21:537-44.
80. Marwick T, Willemart B, D'Hondt AM, Baudhuin T, Wijns W, Detry JM, et al. Selection of the optimal nonexercise stress for the evaluation of ischemic regional myocardial dysfunction and malperfusion. Comparison of dobutamine and adenosine using echocardiography and <sup>99m</sup>Tc-MIBI single photon emission computed tomography. *Circulation* 1993;87:345-54.
81. Senior R, Sridhara BS, Anagnostou E, Handler C, Raftery EB, Lahiri A. Synergistic value of simultaneous stress dobutamine sestamibi sin-

- gle-photon-emission computerized tomography and echocardiography in the detection of coronary artery disease. *Am Heart J* 1994;128:713-8.
82. Mairesse GH, Marwick TH, Vanoverschelde JL, Baudhuin T, Wijns W, Melin JA, et al. How accurate is dobutamine stress electrocardiography for detection of coronary artery disease? Comparison with two-dimensional echocardiography and technetium-99m methoxyisobutyl isonitrile (mibi) perfusion scintigraphy. *J Am Coll Cardiol* 1994;24:920-7.
  83. Levine MG, Ahlberg AW, Mann A, White MP, McGill CC, Mendes de Leon C, et al. Comparison of exercise, dipyridamole, adenosine, and dobutamine stress with the use of Tc-99m tetrofosmin tomographic imaging. *J Nucl Cardiol* 1999;6:389-96.
  84. Santos-Ocampo CD, Herman SD, Travin MI, Garber CE, Ahlberg AW, Messinger DE, et al. Comparison of exercise, dipyridamole, and adenosine by use of technetium 99m sestamibi tomographic imaging. *J Nucl Cardiol* 1994;1:57-64.
  85. Brown KA. Prognostic value of thallium-201 myocardial perfusion imaging. A diagnostic tool comes of age. *Circulation* 1991;83:363-81.
  86. Silverman K, Becker L, Bulkley B, Burow R, Mellits E, Kallman C, et al. Value of early thallium-201 scintigraphy for predicting mortality in patients with acute myocardial infarction. *Circulation* 1980;61:996-1003.
  87. Brown K, Boucher C, Okada R, Gurney T, Newell J, Strauss H, et al. Prognostic value of exercise thallium-201 imaging in patients presenting for evaluation of chest pain. *J Am Coll Cardiol* 1983;1:994-1001.
  88. Gibson R, Watson D, Craddock G, Crampton R, Kaiser D, Denny M, et al. Prediction of cardiac events after uncomplicated myocardial infarction: a prospective study comparing pre-discharge exercise thallium-201 scintigraphy and coronary angiography. *Circulation* 1983;68:321-36.
  89. Ladenheim M, Pollock B, Rozanski A, Berman D, Staniloff H, Forrester J, et al. Extent and severity of myocardial hypoperfusion as predictors of prognosis in patients with suspected coronary artery disease. *J Am Coll Cardiol* 1986;7:464-71.
  90. Kaul S, Lilly D, Gascho J, Watson D, Gibson R, Oliner C, et al. Prognostic utility of the exercise thallium-201 test in ambulatory patients with chest pain: comparison with cardiac catheterization. *Circulation* 1988;77:745-58.
  91. Wackers F, Russo D, Russon D, Clements J. Prognostic significance of normal quantitative planar thallium-201 stress scintigraphy in patients with chest pain. *J Am Coll Cardiol* 1985;6:27-30.
  92. Wahl J, Hakki A, Iskandrian A. Prognostic implications of normal exercise thallium-201 images. *Arch Intern Med* 1985;145:253-6.
  93. Younis L, Byers S, Shaw L, Barth G, Goodgold H, Chaitman B. Prognostic importance of silent myocardial ischemia detected by intravenous dipyridamole thallium myocardial imaging in asymptomatic patients with coronary artery disease. *J Am Coll Cardiol* 1989;14:1635-41.
  94. Hendel R, Layden J, Leppo J. Prognostic value of dipyridamole thallium scintigraphy for evaluation of ischemic heart disease. *J Am Coll Cardiol* 1990;15:109-16.
  95. Kaul S, Boucher C, Newell J, Chesler D, Greenberg J, Okada R, et al. Determination of the quantitative thallium imaging variables that optimize detection of coronary artery disease. *J Am Coll Cardiol* 1986;7:527-37.
  96. Gill J, Ruddy T, Newell J, Finkelstein D, Straus H, Boucher C. Prognostic importance of thallium uptake by the lungs during exercise in coronary artery disease. *N Engl J Med* 1987;317:1486-9.
  97. Boucher C, Zir L, Beller G, Okada R, McKusick K, Strauss H, et al. Increased lung uptake of thallium-201 during exercise myocardial imaging: clinical, hemodynamic and angiographic implications in patients with coronary artery disease. *Am J Cardiol* 1980;46:189-96.
  98. Weiss A, Berman D, Lew A, Nielsen J, Potkin B, Swan H, et al. Transient ischemic dilation of the left ventricle on stress thallium-201 scintigraphy: a marker of severe and extensive coronary artery disease. *J Am Coll Cardiol* 1987;9:752-9.
  99. Iskander S, Iskandrian AE. Risk assessment using single-photon emission computed tomographic technetium-99m sestamibi imaging. *J Am Coll Cardiol* 1998;32:57-62.
  100. Berman DS, Hachamovitch R, Kiat H, Cohen I, Cabico JA, Wang FP, et al. Incremental value of prognostic testing in patients with known or suspected ischemic heart disease: a basis for optimal utilization of exercise technetium-99m sestamibi myocardial perfusion single-photon emission computed tomography [published erratum appears in *J Am Coll Cardiol* 1996;27:756]. *J Am Coll Cardiol* 1995;26:639-47.
  101. Marwick TH, Shaw LJ, Lauer MS, Kesler K, Hachamovitch R, Heller GV, et al. The noninvasive prediction of cardiac mortality in men and women with known or suspected coronary artery disease. Economics of Noninvasive Diagnosis (END) Study Group. *Am J Med* 1999;106:172-8.
  102. Hachamovitch R, Berman DS, Kiat H, Bairey CN, Cohen I, Cabico A, et al. Effective risk stratification using exercise myocardial perfusion SPECT in women: gender-related differences in prognostic nuclear testing. *J Am Coll Cardiol* 1996;28:34-44.
  103. Hachamovitch R, Berman DS, Shaw LJ, Kiat H, Cohen I, Cabico JA, et al. Incremental prognostic value of myocardial perfusion single photon emission computed tomography for the prediction of cardiac death: differential stratification for risk of cardiac death and myocardial infarction [published erratum appears in *Circulation* 1998;98:190]. *Circulation* 1998;97:535-43.
  104. Berman DS, Kang X, Van Train KF, Lewin HC, Cohen I, Areeada J, et al. Comparative prognostic value of automatic quantitative analysis versus semiquantitative visual analysis of exercise myocardial perfusion single-photon emission computed tomography. *J Am Coll Cardiol* 1998;32:1987-95.
  105. Mock M, Ringqvist I, Fisher L, Davis G, Alderman E, Ryan T, et al. Survival of medically treated patients in the Coronary Artery Surgery Study (CASS) registry. *Circulation* 1982;66:562-8.
  106. Pryor D, Harrell F, Lee K, Rosati R, Coleman R, Cobb F, et al. Prognostic indicators for radionuclide angiography in medically treated patients with coronary artery disease. *Am J Cardiol* 1984;53:18-22.
  107. Bonow R, Kent K, Rosing D, Lan K, Lakatos E, Borer J, et al. Exercise-induced ischemia in mildly symptomatic patients with coronary artery disease and preserved left ventricular function: identification of subgroups at risk of death during medical therapy. *N Engl J Med* 1984;311:1339-45.
  108. Lee K, Pryor D, Pieper K, Harrell F, Califf R, Mark D, et al. Prognostic value of radionuclide angiography in medically treated patients with coronary artery disease: a comparison with clinical and catheterization variables. *Circulation* 1990;82:1705-17.
  109. Boucher C, Brewster D, Darling R, Okada R, Strauss H, Pohost G. Determination of cardiac risk by dipyridamole-thallium imaging before peripheral vascular surgery. *N Engl J Med* 1985;312:389-94.
  110. Eagle K, Coley C, Newell J, Brewster D, Darling R, Strauss H, et al. Combining clinical and thallium data optimized preoperative assessment of cardiac risk before major vascular surgery. *Ann Intern Med* 1989;110:859-66.
  111. Mangano D, London M, Tubau J, Browner W, Hollenberg M, Krupski W, et al, and the Study of Perioperative Ischemia Research Group. Dipyridamole thallium-201 scintigraphy as a preoperative screening test: a reexamination of its predictive potential. *Circulation* 1991;84:493-502.
  112. Multicenter Post-infarction Research Group. Risk stratification and survival after myocardial infarction. *N Engl J Med* 1983;309:331-6.
  113. Leppo J, O'Brien J, Rothendler J, Getchell J, Lee V. Dipyridamole-thallium-201 scintigraphy in the prediction of future cardiac events after acute myocardial infarction. *N Engl J Med* 1984;310:1014-8.
  114. DeCoster P, Wijns W, Cauwe F, Robert A, Beckers C, Melin J. Area-at-risk determination by technetium-99m-hexakis-2-methoxyisobutyl isonitrile in experimental reperfused myocardial infarction. *Circulation* 1990;82:2152-62.

115. Wackers F, Terrin M, Kayden D, Knatterud G, Forman S, Braunwald E, et al. Quantitative radionuclide assessment of regional ventricular function after thrombolytic therapy for acute myocardial infarction: results of phase I Thrombolysis In Myocardial Infarction (TIMI) trial. *J Am Coll Cardiol* 1989;13:998-1005.
116. Gibbons R, Verani M, Behrenbeck T, Pellikka P, O'Connor M, Mahmarian J, et al. Feasibility of tomographic <sup>99m</sup>Tc-hexakis-2-methoxy-2-methylpropyl-isonitrile imaging for the assessment of myocardial area at risk and the effect of acute treatment in myocardial infarction. *Circulation* 1989;80:1277-86.
117. Faraggi M, Bok B. Role of technetium <sup>99m</sup> methoxyisobutylisonitrile single photon emission tomography in the evaluation of thrombolysis in acute myocardial infarction before and after admission to hospital. Multicenter Study Group "Etude MIBI (EMIBI)." *Eur J Nucl Med* 1991;18:91-8.
118. Dewhurst N, Muir A. Comparative prognostic value of radionuclide ventriculography at rest and during exercise in 100 patients after first myocardial infarction. *Br Heart J* 1983;49:111-21.
119. Zaret BL, Wackers FJ, Terrin ML, Forman SA, Williams DO, Knatterud GL, et al. Value of radionuclide rest and exercise left ventricular ejection fraction in assessing survival of patients after thrombolytic therapy for acute myocardial infarction: results of Thrombolysis in Myocardial Infarction (TIMI) phase II study. The TIMI Study Group. *J Am Coll Cardiol* 1995;26:73-9.
120. Hung J, Goris M, Nash E, Kraemer H, DeBusk R, Berger WI, et al. Comparative value of maximal treadmill testing, exercise thallium myocardial perfusion scintigraphy and exercise radionuclide ventriculography for distinguishing high- and low-risk patients soon after acute myocardial infarction. *Am J Cardiol* 1984;53:1221-7.
121. Abraham R, Freedman S, Dunn R, Newman H, Roubin G, Harris P, et al. Prediction of multivessel coronary artery disease and prognosis early after acute myocardial infarction by exercise electrocardiography and thallium-201 myocardial perfusion scanning. *Am J Cardiol* 1986;58:423-7.
122. Becker L, Silverman K, Bulkley B, Kallman C, Mellits E, Weisfeldt M. Comparison of early thallium-201 scintigraphy and gated blood pool imaging for predicting mortality in patients with acute myocardial infarction. *Circulation* 1983;67:1272-82.
123. Gibson R, Watson D, Taylor G, Crosby I, Wellons H, Holt N, et al. Prospective assessment of regional myocardial perfusion before and after coronary revascularization surgery by quantitative thallium-201 scintigraphy. *J Am Coll Cardiol* 1983;1:804-15.
124. Kiat H, Berman DS, Maddahi J, De Yang L, Van Train K, Rozanski A, et al. Late reversibility of tomographic myocardial thallium-201 defects: an accurate marker of myocardial viability. *J Am Coll Cardiol* 1988;12:1456-63.
125. Dilsizian V, Rocco T, Freedman N, Leon M, Bonow R. Enhanced detection of ischemic but viable myocardium by the reinjection of thallium after stress-redistribution imaging. *N Engl J Med* 1990;323:141-6.
126. Tilkemeier P, Guiney T, LaRaia P, Boucher C. Prognostic value of pre-discharge low level exercise thallium testing after thrombolytic treatment of acute myocardial infarction. *Am J Cardiol* 1990;66:1203-9.
127. Sutton J, Topol E. Significance of a negative exercise thallium test in the presence of a critical residual stenosis after thrombolysis for acute myocardial infarction. *Circulation* 1991;83:1278-86.
128. Travin M, Dessouki A, Cameron T, Heller G. Use of exercise technetium-99m sestamibi SPECT imaging to detect residual ischemia and for risk stratification after acute myocardial infarction. *Am J Cardiol* 1995;75:665-9.
129. Brown K, Heller G, Landin R, Shaw L, Beller G, Pasquale M, et al. Early dipyridamole <sup>99m</sup>Tc-sestamibi single photon emission computed tomographic imaging 2-4 days after acute myocardial infarction predicts in-hospital and post-discharge cardiac events: comparison with submaximal exercise imaging. *Circulation* 1999;100:2060-6.
130. Berger BC, Watson DD, Burwell LR, Crosby IK, Wellons HA, Teates CD, et al. Redistribution of thallium at rest in patients with stable and unstable angina and the effect of coronary artery bypass surgery. *Circulation* 1979;60:1114-25.
131. Dilsizian V, Perrone-Filardi P, Arrighi JA, Bacharach SL, Quyyumi AA, Freedman NM, et al. Concordance and discordance between stress-redistribution-reinjection and rest-redistribution thallium imaging for assessing viable myocardium. Comparison with metabolic activity by positron emission tomography. *Circulation* 1993;88:941-52.
132. Ragosta M, Beller GA, Watson DD, Kaul S, Gimple LW. Quantitative planar rest-redistribution <sup>201</sup>Tl imaging in detection of myocardial viability and prediction of improvement in left ventricular function after coronary bypass surgery in patients with severely depressed left ventricular function. *Circulation* 1993;87:1630-41.
133. Udelson JE, Coleman PS, Metherall J, Pandian NG, Gomez AR, Griffith JL, et al. Predicting recovery of severe regional ventricular dysfunction. Comparison of resting scintigraphy with <sup>201</sup>Tl and <sup>99m</sup>Tc-sestamibi. *Circulation* 1994;89:2552-61.
134. Sawada SG, Allman KC, Muzik O, Beanlands RS, Wolfe ER Jr, Gross M, et al. Positron emission tomography detects evidence of viability in rest technetium-99m sestamibi defects. *J Am Coll Cardiol* 1994;23:92-8.
135. Althoefer C, vom Dahl J, Biedermann M, Uebis R, Beilin I, Sheehan F, et al. Significance of defect severity in technetium-99m-MIBI SPECT at rest to assess myocardial viability: comparison with fluorine-18-FDG PET. *J Nucl Med* 1994;35:569-74.
136. Maurea S, Cuocolo A, Pace L, Nicolai E, Nappi A, Imbriaco M, et al. Left ventricular dysfunction in coronary artery disease: comparison between rest-redistribution thallium 201 and resting technetium 99m methoxyisobutyl isonitrile cardiac imaging. *J Nucl Cardiol* 1994;1:65-71.
137. Kauffman GJ, Boyne TS, Watson DD, Smith WH, Beller GA. Comparison of rest thallium-201 imaging and rest technetium-99m sestamibi imaging for assessment of myocardial viability in patients with coronary artery disease and severe left ventricular dysfunction. *J Am Coll Cardiol* 1996;27:1592-7.
138. Levine MG, McGill CC, Ahlberg AW, White MP, Giri S, Shareef B, et al. Functional assessment with electrocardiographic gated single-photon emission computed tomography improves the ability of technetium-99m sestamibi myocardial perfusion imaging to predict myocardial viability in patients undergoing revascularization. *Am J Cardiol* 1999;83:1-5.
139. Galassi AR, Tamburino C, Grassi R, Foti R, Mammana C, Virgilio A, et al. Comparison of technetium 99m-tetrofosmin and thallium-201 single photon emission computed tomographic imaging for the assessment of viable myocardium in patients with left ventricular dysfunction. *J Nucl Cardiol* 1998;5:56-63.
140. Flotats A, Carrio I, Estorch M, Berna L, Catafau AM, Mari C, et al. Nitrate administration to enhance the detection of myocardial viability by technetium-99m tetrofosmin single-photon emission tomography. *Eur J Nucl Med* 1997;24:767-73.
141. Matsunari I, Fujino S, Taki J, Senma J, Aoyama T, Wakasugi T, et al. Myocardial viability assessment with technetium-99m-tetrofosmin and thallium-201 reinjection in coronary artery disease. *J Nucl Med* 1995;36:1961-7.
142. Cuocolo A, Nicolai E, Soricelli A, Pace L, Nappi A, Sullo P, et al. Technetium 99m-labeled tetrofosmin myocardial tomography in patients with coronary artery disease: comparison between adenosine and dynamic exercise stress testing. *J Nucl Cardiol* 1996;3:194-203.